

Yale University

## EliScholar – A Digital Platform for Scholarly Publishing at Yale

---

Yale Medicine Thesis Digital Library

School of Medicine

---

January 2014

# Skin Toxicity Associated With Clofarabine And Cytarabine For The Treatment Of Acute Leukemia

Bingnan Zhang

Yale School of Medicine, zbingnan@gmail.com

Follow this and additional works at: <http://elischolar.library.yale.edu/ymtdl>

---

### Recommended Citation

Zhang, Bingnan, "Skin Toxicity Associated With Clofarabine And Cytarabine For The Treatment Of Acute Leukemia" (2014). *Yale Medicine Thesis Digital Library*. 1938.

<http://elischolar.library.yale.edu/ymtdl/1938>

This Open Access Thesis is brought to you for free and open access by the School of Medicine at EliScholar – A Digital Platform for Scholarly Publishing at Yale. It has been accepted for inclusion in Yale Medicine Thesis Digital Library by an authorized administrator of EliScholar – A Digital Platform for Scholarly Publishing at Yale. For more information, please contact [elischolar@yale.edu](mailto:elischolar@yale.edu).

Skin toxicity associated with clofarabine and cytarabine for the  
treatment of acute leukemia

A Thesis Submitted to the  
Yale University School of Medicine  
in Partial Fulfillment of the Requirements for the  
Degree of Doctor of Medicine

by

Bingnan Zhang

2014

## **Abstract**

Authors: Bingnan Zhang, Jean Bologna, Peter Marks, and Nikolai Podoltsev, Department of Internal Medicine, Yale School of Medicine, New Haven, Connecticut

Skin toxicity is associated with a number of different chemotherapeutic agents used to treat acute leukemias, including cytarabine, daunorubicin, doxorubicin, and methotrexate. While alopecia and radiation recall are well-recognized cutaneous side effects, more recently the term "toxic erythema of chemotherapy" (TEC) has been coined to describe a spectrum of skin findings, ranging from palmar-plantar erythrodysesthesia to erythema of major body folds, with erythroderma representing its most severe form. In this retrospective study of 49 patients with acute leukemia, 10 patients were treated with clofarabine alone (40 mg/m<sup>2</sup> daily for 5 days) and 40 patients received this dose of clofarabine plus cytarabine (1 g/m<sup>2</sup> daily for 5 days); one patient received each of the two regimens with an interval of 6 weeks between administrations. Treatment-associated skin toxicity, including TEC, developed 3 to 9 days following the initiation of chemotherapy and was more common in the group receiving the two-drug combination as compared to those receiving clofarabine alone (22/40 [55%] versus 1/10 [10%] respectively; p=0.014). The

majority of chemotherapy-related cutaneous side effects represented TEC. Clinicians should be aware of the potential for additive or synergistic skin toxicity in the setting of the combination of clofarabine and cytarabine.

## **Acknowledgements**

I would like to thank my mentors: Drs. Peter Marks and Nikolai Podoltsev, without whose generous support and guidance I would not have been able to accomplish this project. They are also outstanding clinicians and role models who inspire me everyday.

I would also like to thank Dr. Jean Bologna, for her generous guidance and advice throughout this project.

I would like to acknowledge Katherine Mandock, who meticulously extracted the pharmacy data used in this project.

At last but not the least, I would like to thank my husband and my parents who have always been so supportive and encouraging to my endeavors in every step of the way.

**Table of Contents** (with page numbers for each section)

**Introduction**

- a. Overview of mucocutaneous toxicity of chemotherapy agents ---P1
- b. Toxic erythema of chemotherapy (TEC) -----P13
- c. Overview of Clofarabine and cytarabine and their skin toxicities-P17

**Statement of purpose and hypothesis** -----P23

**Methods** ----- P23

**Results** -----P25

**Discussion** -----P29

**References** ----- P32

**Figures** -----P42

**Tables** -----P45

**Appendix** -----P47

**Introduction:***a. Overview of mucocutaneous toxicity of chemotherapy agents*

Chemotherapy is an important treatment modality for multidisciplinary cancer management. Cancer is the second leading cause of death only after heart disease. According to the American Cancer Society, in 2013, there were estimated 1.7 million new cancer cases and 580,350 deaths due to cancer, which represents approximately 1,600 deaths per day or one in every four deaths.(1)

Various types of mucocutaneous reactions commonly occur in patients undergoing chemotherapy, including drug hypersensitivities, skin changes due to graft versus host disease (GVHD) and infections in neutropenic patients. Therefore correct attribution of the cause of the skin reactions is important for appropriate patient management. Understanding the potential risk associated with a given chemotherapy agent facilitates the distinction of the most likely offending drug causing a mucocutaneous reaction from a variety of other medications that are being concomitantly administered. It also facilitates appropriate counseling of patients about potential side effects of the chemotherapy agents that are to be administered. Mucocutaneous

reactions are frequent and visible, thus recognizing them early and starting proper prophylaxis or treatment play an important role in cancer patients' psychological health and quality of life.

More than fifty mucocutaneous toxicities have been described in the literature with over thirty chemotherapy agents.(2, 3). Herein described are the most common types of mucocutaneous toxicities associated with chemotherapeutic agents, including a spectrum of overlapping painful erythemas collectively called toxic erythema of chemotherapy (TEC).(4)

#### *Acneiform eruptions*

Acneiform eruptions, or papulopustular eruptions, are characterized by sterile pustules and erythematous papules. They are commonly distributed in the seborrheic areas, including the scalp, face, neck, central chest, upper back, and behind the ears; palms and soles are spared.(5, 6) Most frequently reported with the use of epidermal growth factor receptor (EGFR) inhibitors, acneiform eruptions are generally self-limited and dose-dependent. The acne-like rash has been reported as a side effect with increased frequency in patients treated with gefitinib, erlotinib and cetuximab.(7-9) Interestingly, a



number of studies have suggested that the severity of acneiform eruption is positively associated with the tumor response to EGFR inhibitors and overall survival.(10-12) However, prospective studies are needed to examine the association between dermatologic eruption and tumor response.

The widespread pustules of acneiform eruptions could look alike with bacterial infections, steroid acne, or disseminated herpes zoster. Therefore appropriate tests such as culture of the pustules to rule out any infections are necessary to confirm the diagnosis of acneiform eruptions.(13) Tetracyclines have been shown to have efficacy in acneiform eruption prophylaxis in cetuximab therapy.(14) There is no standard therapy for acneiform eruptions. Several strategies that have been described include tetracyclines, metronidazole, clindamycin gel, and topical and oral steroids in severe cases.(15, 16)

### *Hair changes*

Anagen, catagen and telogen complete the three phases of hair growth. A number of chemotherapeutic agents induce hair loss (alopecia) by one of two mechanisms: anagen effluvium and telogen effluvium. Anagen is the active phase of hair growth; anagen

effluvium is defined as the pathologic loss of the anagen phase of hair, which typically occurs within two to three weeks of the administration of chemotherapeutic agents. Telogen is the follicular resting phase of hair growth, telogen effluvium occurs later, about two to four months after drug administration.(17) Alopecia can be caused by most chemotherapeutic agents; including taxanes, etoposide, bleomycin, dactinomycin, cytarabine and vinca alkaloids.(18, 19) However, liposomal anthracyclines and gemcitabine rarely induce alopecia.(19, 20) On the other hand, trichomegaly and abnormal hair growth have also been reported with the use of EGFR inhibitors.(21-23)

In most cases, abnormal hair growth and alopecia resolve spontaneously after cessation of the offending drugs. A few treatment strategies have been explored to prevent or delay the onset of alopecia in human and animal models. Application of a scalp tourniquet and various drugs such as minoxidil have shown limited success.(24, 25) In a recent prospective randomized trial, scalp cooling reduced risk of alopecia occurrence by 78% in patients treated with docetaxel.(26)

*Erythema multiforme, Stevens-Johnson syndrome/toxic epidermal necrolysis*

Erythema multiforme (EM) is an acute, immune-mediated mucocutaneous reaction caused by medications and certain infections, most commonly herpes simplex virus. EM lesions are characterized by targetoid erythematous plaques with central color variations.(27) These lesions are usually on acral surfaces, however mucosal involvement can occur in up to 60% of the cases.(28) Stevens-Johnson syndrome/toxic epidermal necrolysis (SJS/TEN) is a spectrum of mucocutaenous lesions distinct from EM. The lesions in SJS/TEN are typically erythematous or pruritic macules that are more predominant on the face and trunk as apposed to the acral distribution in EM.(27) Mucous membranes are involved in almost all cases. The difference between SJS and TEN is the degree of the involvement by epidermal detachment; with SJS involving less than 10%, and TEN involving more than 30% of the total body surface area. If the epidermal detachment involves 10%-30% of the body surface area, it is denoted as the SJS/TEN overlapping syndrome. Recent studies have shown that certain human leukocyte antigens (HLA) alleles are associated with the activation of cytotoxic T cells that initiate SJS/TEN.(29) Therefore different drug antigens and the genetic make-up of the patient may provide different predisposition for this immune-mediated process.(30, 31)

Several chemotherapy agents have been implicated in EM, such as docetaxel and flurouracil.(32, 33) Other than removing offending drugs, there are no controlled studies demonstrating efficacy of systemic corticosteroids treatment for drug-induced EM. However, symptom management such as with antiseptic/antihistamine rinses and local anesthetic solutions are beneficial.(34) SJS/TEN has been observed with concurrent gemcitabine and radiation therapy, as well as with rituximab and as localized epidermal necrolysis of the skin over vinblastine infusion site.(35-37) The management of SJS/TEN entails meticulous supportive care similar to that for burn patients, including antiseptics to minimize infection and sepsis risk, electrolytes and fluid repletion, wound care, and eye ointment. The use of systemic corticosteroids and IVIG remains uncertain as there is no prospective trial conducted to date.(38, 39)

### *Hypersensitivity*

Hypersensitivity reactions to chemotherapeutic agents are immune-mediated allergic reactions. There are four types of hypersensitivity reactions, as defined by Gell and Coombs. Type I hypersensitivity is IgE antibody mediated response; Type II is IgG or IgM mediated cytotoxic response; Type III is immune-complex

mediated response; and Type IV is delayed, cell-mediated response.(40) Type I responses are immediate reactions, sometimes called anaphylactic hypersensitivities; its symptoms can range from minor pruritus, flushing, wheals formation on the skin and mucous secretion, to hypotension, angioedema, and death. Anaphylactic reactions have been reported with paclitaxel and platinum based agents such as carboplatin.(3) In the case of paclitaxel, prophylactic premedication with anti-histamines and corticosteroids before drug infusion is now routinely used, however hypersensitivity may still occur in 2-5% of patients.(41) For carboplatin, antihistamines may be helpful for mild cases, but premedication with corticosteroids and antihistamines are not sufficient for more severe reactions involving the respiratory system, in which case, the discontinuation of the drug, or switch to a different platinum-based medication are recommended.(42, 43)

Type II hypersensitivity includes immune thrombocytopenia, neutropenia, and hemolytic anemia; and type III responses typically can manifest as vasculitis and serum sickness syndrome. Many monoclonal antibodies such as rituximab, alemtuzumab, alemtuzumab, and bevacizumab are thought to cause type II and type III hypersensitivity reactions. For example, rituximab has been reported

to cause immune mediated thrombocytopenia, neutropenia, hemolytic anemia, as well as allergic vasculitis and serum sickness-like reactions.(44-47) Type IV hypersensitivity are delayed reactions that generally develop hours to days after exposure. Examples of drug-induced type IV reactions include drug reaction with eosinophilia and systemic symptoms (DRESS), fixed drug eruptions, SJS, TEN, and EM.(48) They are characterized by pruritic, erythematous papules and/or plaques, or a morbilliform drug eruption. Cladribine associated hypersensitivity, which causes cutaneous reactions and peripheral eosinophilia, is thought to be a delayed hypersensitivity (type IV).(49) A bullous fixed drug eruption has been associated with paclitaxel. It is clinically characterized by bullae formation over dusky erythematous patches and development of ulcers after bullae rupture. It tends to occur within the first two days after paclitaxel infusion and re-exposure of paclitaxel will cause bullous response to recur within the same anatomical region.(50) There are no treatment guidelines for chemotherapy-induced hypersensitivity. Desensitization and premedication with steroids and antihistamines may be helpful, however, in severe cases discontinuation of the drug is recommended.

### *Hyperpigmentation*

Hyperpigmentation is another common manifestation of cutaneous toxicity due to chemotherapy. For example, Fluorouracil administration may cause patchy, reticulate and mottled hyperpigmentation.(51) Cyclophosphamide can cause diffuse hyperpigmentation of the mucosa, teeth, tongue, nails, palms and soles, with nail pigmentation being the most common.(52, 53) A recent case report describes a patient who developed generalized reticulated pigmentation on the face, trunk and extremities after receiving cyclophosphamide, which cleared gradually in the next seven months, but the pigmentation aggravated when cyclophosphamide was resumed. The histology of skin biopsy showed "hyperplasia, parakeratosis and multiple necrotic keratinocytes in the epidermis".(52) Brownish pigmentation of the nails is commonly seen with hydroxyurea. In addition, it has been reported that hydroxyurea can cause blue discoloration of the lunula.(54) The exact mechanism of the nail pigmentation is not clear, but it may be caused by focal stimulation of melanocytes leading to deposition of melanin in the nail matrix or a direct toxic effect on the distal nail matrix basal cells.(55) Weekly intravenous infusion of docetaxel has been reported to cause a supragenous red skin pigmentation above the infusion site, without evidence of infiltration of the veins or phlebitis.(56) Although docetaxel may increase the permeability of the vascular endothelium and lead to

edema, the mechanism of this discoloration is not clear.(57) Anthracyclines such as daunorubicin occasionally cause skin hyperpigmentation in both sun-exposed and sun-protected areas. The proposed mechanism is damage and subsequently repair of melanocytes by intercalation of anthracyclines resulting in hyperpigmentation of the skin.(58) Recently a case of palatal melanosis was reported in a patient receiving Imatinib for chronic myelogenous leukemia, which adds to the previously known side effects of hypopigmentation or hyperpigmentation in imatinib.(59) The proposed mechanism of imatinib-induced hypo- or hyper-pigmentation is that the receptor tyrosine kinase c-Kit plays important regulatory roles in melanogenesis, pigmentation and melanocyte homeostasis.(60)

Chemotherapy induced hyperpigmentation generally resolves over months to years.(51) Topical retinoids may be beneficial to stimulate rapid turnover of keratinocytes with subsequent loss of melanin. Topical products containing hydroquinone and corticosteroids may also decrease melanin synthesis. Avoidance of sun exposure and use of sunscreens can minimize progression of pigmentation.(13)

*Xerosis*



Xerosis, or dry skin, can occur with several chemotherapy agents, appearing several weeks after treatment in up to 35% of patients in clinical trials.(10) Patients often complain of dry skin, pain and itchiness. Left unattended, xerosis can evolve into asteatotic eczema, which can lead to secondary *Staphylococcus aureus* or *Herpes simplex* infections.(61) It is a common side effect with administration of epidermal growth factor receptor (EGFR) inhibitors such as cetuximab. EGFR inhibition causes keratinocyte growth arrest and initiate terminal differentiation of basal keratinocytes in vitro, which could explain the clinical presentation of fine scaling in xerosis. Histologic changes are subtle in the epidermis, with loss of the basket-weave appearance in the thin stratum corneum, and compact on with parakeratosis.(62) In addition to diffuse dry skin, several patients treated with Gefitinib reported vaginal dryness and itching, perineal dryness, and eye irritations including blepharitis.(63)

Preventative measures for xerosis include frequent use of moisturizing emollients, avoiding soap, and application of short showers with decreased water temperature. Xerosis and desquamation can be treated with emollients such as petroleum jelly and Aquaphor®, or standard emollients such as 5-10% urea in cetomacrogol cream.(64) Topical corticosteroids can be used intermittently to treat eczema,

however long term use should be avoided to reduce the risk of steroid atrophy.

### *Miscellaneous*

Many other skin toxicities have been associated with various chemotherapeutic agents. Autoimmune phenomena such as scleroderma and Raynaud's phenomenon have been associated with the use of bleomycin.(65) Lupus erythematosus and dermatomyositis-like eruptions are found with hydroxyurea administration.(66) Hydroxyurea also induces nail changes including brittle nails, longitudinal or transverse bands, and brownish pigmentation.(54) The incidence of extravasation from systemic chemotherapy infusion has been decreasing with the awareness and use of central catheters and ports. However, tissue necrosis from anthracycline extravasation happens slowly and can be missed, with catastrophic consequences.(67) A tissue recall phenomenon can occur with various agents including adriamycin, docetaxel, and epirubicin, where tissue necrosis happens at a site of prior tissue damage even if the chemotherapeutic agent is administered through different extremities.(68) Mucositis is another common side effect associated with several agents including methotrexate, cytarabine and

fluorouracil.(69) Mucositis is typically dose-dependent, and it can be life threatening in the case of gastrointestinal mucosal damage.(70)

### b. Toxic Erythema of Chemotherapy (TEC)

#### *Definition*

Toxic erythema of chemotherapy (TEC) is a clinicopathological term suggested by Bologna and others to unify a group of overlapping toxic skin reactions following chemotherapy.(4) The cutaneous findings range from painful palmar-plantar erythrodysesthesia (hand-foot syndrome) to dusky erythema of the major body folds. These lesions are characterized by painful and often edematous erythema most commonly involving hands and feet, intertriginous areas such as axilla and groin, and less often, the elbows, knees, neck, and ears.(4) (Figure 1) Previously, multiple clinical and histological names have been used to describe these skin eruptions. For example, terms including "hand-foot syndrome", "palmar-plantar erythema", "palmar-plantar erythrodysesthesia" and "acral erythema" have all been used to describe the cutaneous toxic effects of chemotherapy manifested on hands and feet.(71-74) However, the same appearance of the erythematous patches that develop edema, desquamation, bullae, or

purpura, can also be found in other areas of the body. "Ara-C ears" is one example that describes painful erythema and swelling of the ears after cytarabine administration.(75) Therefore a simplified term to describe the spectrum of these localized erythematous eruptions can avoid confusion and rule out differential diagnoses such as infection, allergy, or graft-versus-host-disease (GVHD). The onset of localized TEC is usually between 2 days to 3 weeks following the chemotherapy administration. There is associated pain, burning, pruritus, and paresthesia sensation on the skin lesions. Typically desquamation and spontaneous resolution of the skin lesions happen without specific therapy.(76, 77)

A more generalized form of TEC is erythroderma, defined as generalized erythema and scaling involving more than 90% of the skin surface. The term is not a discrete entity, but rather a presentation of underlying causes such as atopic dermatitis, psoriasis, cutaneous T cell lymphoma (CTCL) or drug reactions.(78) In the context of chemotherapeutic agents, development of erythroderma can be viewed as a generalized, and sometimes more severe, form of TEC. The clinical features of erythroderma include pruritus, scaling, bullae formation, and intense pruritus resulting in scratch induced lichenification.(78) Extensive erythroderma resembles severe sunburn,

including being followed by desquamation, but without sparing of non-sun-exposed sites. See figure 2 for a schematic summary of the spectrum of toxic erythema of chemotherapy.

### *Diagnosis and treatment*

The prompt recognition and diagnosis of TEC is important because the alternative differential diagnoses such as infections, GVHD, or allergic reactions require immediate management plans. Staggering numbers of chemotherapeutic agents can cause TEC. The most common drugs associated with localized TEC are cytarabine, anthracyclines, 5-fluorouracil, capecitabine, taxanes and methotrexate.(4) Histologically, local TEC, such as palmar-plantar erythrodysesthesia, lacks specific findings. Scattered necrotic and dyskeratotic keratinocytes, basal layer vacuolar degeneration, dermal edema, and eccrine squamous syringometaplasia and/or eccrine hidradenitis are frequently described.(77, 79)

There is no specific standard treatment for TEC. The main management strategy for TEC is symptomatic support to lessen pain, edema, and to prevent super-infection. Most localized TEC lesions resolve within a month after dose modification or cessation of the

causative agent(s). Other therapies described in small series have showed some efficacy, however large trials are lacking. Ice packs applied around wrists and ankles in patients treated with liposomal doxorubicin have led to reduced incidence of palmar-plantar erythrodysesthesia.(80) Oral dexamethasone has also been shown to alleviate localized TEC in patients undergoing liposomal doxorubicin treatment.(81) Other treatments suggested in case reports and retrospective studies include topical DMSO and COX2 inhibitors.(82, 83) A recent single-institution phase III trial showed celecoxib reduced incidence of hand-foot syndrome in patients treated with capecitabine.(84) Though some literature suggests that oral pyridoxine might provide benefit for the prevention or treatment of palmar-plantar erythrodysesthesia, strong evidence of any proving treatment is lacking.(85) Two double-blinded randomized trials recently did not show prevention of hand-foot syndrome in patients received oral pyridoxine versus placebo.(86, 87) Dose modification or treatment cessation remains the main strategy if TEC develops.(82, 83)

The chemotherapeutic agents most frequently associated with erythroderma are bevacizumab, imatinib, isotretinoin and thalidomide.(88) The diagnosis of erythroderma can be made based on its clinical presentation of erythema and scaling involving more than

90% of the total body surface area. The histologic features of drug-induced erythroderma are often nonspecific, with necrotic keratinocytes, vacuolar changes and inflammatory infiltrates.(89) Supportive treatment for erythroderma includes maintaining fluid and electrolyte balance, preventing secondary infections and symptomatically managing inflammation and pruritus. In erythroderma with bullae formation, placing windows in the most dependent portions of bullae in order to allow drainage of initially sterile fluid while preserving the blister roof as a “natural bandage” is helpful. Topical and systemic corticosteroids may be beneficial, but no prospective trials have been done to suggest their efficacy.(90-92) ICU level care may be required for extensive erythroderma. Dose modification and drug cessation remain necessary if severe clinical symptoms develop.

### *c. Overview of cytarabine, clofarabine, and their skin toxicities*

#### *Clofarabine and cytarabine*

Nucleoside analogs have been a class of highly effective agents in the treatment of leukemias, lymphomas and other hematologic disorders. Examples of nucleoside analogs include gemcitabine,

azacitidine, cladribine, cytarabine, and recently, clofarabine.(93-97)

Cytarabine, or cytosine arabinoside (Ara-C), is one of the most active chemotherapeutic agents used in the treatment of leukemias and other hematologic malignancies. It is a synthetic analog of nucleoside cytidine and it differs from cytidine by an additional  $\beta$  - hydroxyl group in the 2' position of the sugar moiety.(98) Cytarabine is metabolized in the liver to its active form aracytidine triphosphate by deoxycytidine kinase and other nucleotide kinases, and is eventually rapidly deaminated to the non-cytotoxic metabolite uracil arabinoside (araU) by deoxycytidine deaminase.(99) Only 5-10% of cytarabine is excreted unchanged through the kidneys.(98)

In 1965, the antineoplastic properties of cytarabine were demonstrated in animal models.(100) Three years later, it was introduced as a treatment for acute leukemia.(101) Cytarabine, in combination with an anthracycline, usually daunorubicin, has served as the standard induction therapy ("7+3") for acute myeloid leukemia (AML) for several decades. It is also used off-label in AML consolidation and salvage therapy, as well as in acute lymphoblastic leukemia (ALL), chronic myeloid leukemia (CML) and lymphomas.(102-106)



Clofarabine, molecular structure (2-chloro-2'-fluoro-deoxy-9- $\beta$ -D-arabinofuranosyladenine), is a second-generation nucleoside analog that combined the most favorable pharmacokinetic characteristics of cladribine and fludarabine with the goal of improving drug efficacy and minimize extramedullary toxicities of the other deoxynucleoside analogues.(107) Clofarabine moves into cells via active nucleoside transport as well as passive transport. In the cell, cellular kinases such as deoxycytidine kinase phosphorylate clofarabine to its active triphosphate form. Due to its higher resistance to phosphorolysis and deamination, clofarabine has greater stability and increased triphosphate retention.(108, 109)

Clofarabine is approved in the United States for the treatment of relapsed or refractory ALL in pediatric population less than 21 years old who had at least two prior treatment regimens.(110) It is also for unlabeled use in refractory ALL and AML as a mono-therapy or combination therapy with cytarabine.(111-113) The 2013 National Comprehensive Cancer Network (NCCN) guidelines indicated that clofarabine could be used as frontline treatment of acute myelocytic leukemia (AML) in adults older than 60 years.(114)

The rationale for combining clofarabine with cytarabine is based

on in-vitro studies showing that when cytarabine is administered after clofarabine, the conversion of cytarabine to its active triphosphate form is increased.(108) Faderl et al. have studied clofarabine and cytarabine combination as an induction therapy for AML in elderly patients. In one of their studies, cytarabine was given at  $1\text{g}/\text{m}^2/\text{d}$  from day 1 to day 5 and Clofarabine was given at  $40\text{mg}/\text{m}^2$  from day 2 to day 6. Cytarabine was administered four hours after clofarabine. The overall response rate was 60%.(115) They subsequently performed a randomized study of clofarabine versus clofarabine plus low-dose cytarabine as the front line therapy for patients 60 years and older with AML and high-risk myelodysplastic syndrome, which showed better event-free-survival (EFS) and complete response (CR) rate with the combination regimen but not overall survival.(112) In a recent phase III trial *CLASSIC I* (Clofarabine and Ara-C Studying Survival Via Induction and Consolidation), Faderl et al compared the combination of clofarabine plus cytarabine with cytarabine alone in older patients with refractory AML, and found better EFS and RR with the combination arm, however there was no OS difference between the arms.(111) Another recent phase II trial studied clofarabine in combination with cytarabine and idarubicin (CIA) as the induction therapy for patients age less than 60 with newly diagnosed AML. The overall response (OR) rate in the study was 79%, and longer overall survival (OS) and EFS

compared to historical patients treated with the cytarabine plus idarubicin regimen.(116)

### *Cutaneous toxicity*

Cutaneous toxicities including TEC are known side effects of cytarabine. The mechanisms of the skin toxicity are not entirely clear. One plausible explanation is the toxicity to the epidermis and the eccrine ducts and glands, which are most concentrated in the skin of palms and feet.(117, 118) The incidence of TEC appears to be dose-related. In a prospective study of skin reactions with high dose cytarabine, rashes occurred in 41% and 73% of patients who received a total dose of 24g/m<sup>2</sup> and 30g/m<sup>2</sup> of cytarabine respectively; of which morbilliform eruptions and acral erythema were most common.(18) High dose cytarabine is also associated with cytarabine syndrome, a rare immune-allergic reaction characterized by fever, bone and chest pain, conjunctivitis, rash, malaise and myalgia.(18)

The package insert of clofarabine reports a 38% incidence of rash, a 13% incidence of erythema, and an 18% incidence of palmar-plantar erythrodysesthesia. In one phase II study with clofarabine 40mg/m<sup>2</sup>/day for 5 days, skin rashes and palmar-plantar

erythrodysesthesia were noted in 66% of patients.(119) There are potential synergistic effects of skin toxicities due to clofarabine and cytarabine combination therapy. In the Phase II trial of clofarabine (40mg/m<sup>2</sup>/day x 5 days) and cytarabine (1g/m<sup>2</sup>/day x 5 days) combination therapy by Faderl et al, skin rash was reported in 12 patients (60%), of whom 9 of developed hand-foot syndrome (45%), which was severe (grade III or IV) in 3 patients (15%).(120) In the subsequent phase III study of the same combination regimen versus cytarabine plus placebo, 15% of patients in the combination arm and 6% of patients in the cytarabine plus placebo arm developed grade 3 to 4 skin and subcutaneous toxicities. Palmar-plantar erythrodysesthesia occurred in 20% of patients in the combination arm and only 1% in the cytarabine plus placebo arm.(111) In two other studies, the combination therapies were associated with skin toxicities ranging from 40 to 82%.(112, 115) In a recent case report, a patient developed extensive TEC involving trunks, leg, feet and hands after receiving the combination therapy with clofarabine (40mg/m<sup>2</sup>/day x 5 days) and cytarabine (1g/m<sup>2</sup>/day x 5 days). The skin lesions deteriorated and developed blisters, and the patient subsequently succumbed to the secondary bacterial infections in the setting of severe granulocytopenia.(121)

## **Statement of purpose and hypothesis**

This study aims to characterize the range of skin toxicities associated with clofarabine as well as clofarabine and cytarabine combination therapy in treatment of acute leukemias at Yale Cancer Center. We hypothesize that there will be additive or synergistic effects of the skin toxicities due to clofarabine and cytarabine combination therapy.

Our secondary purpose is to emphasize the clinical importance of TEC and to increase the awareness of its high incidence in combination chemotherapy regimen, and to avoid misdiagnosis of skin toxicities.

## **Methods**

Institutional review board approval was obtained prior to this retrospective review of medical records of all adult patients with AML or ALL treated with clofarabine, either alone or in combination with cytarabine, at Yale-New Haven Hospital from December 2006 through February 2011. In order to facilitate comparison of the cutaneous toxicity observed following administration of clofarabine versus

clofarabine plus cytarabine, only patients who were treated with clofarabine 40 mg/m<sup>2</sup> daily for 5 days [days 1 to 5] +/- cytarabine (1 g/m<sup>2</sup> daily for 5 days [days 2 to 6]) were included in this analysis. In addition to demographic and chemotherapy regimen data, available records of patients during and after the treatment period were reviewed in detail, including their hospital course, any complications, presence of cutaneous reactions, the description and progression of skin toxicity findings. Clinical criteria and, when available, dermatology consultations and skin biopsy results were used to distinguish TEC from other entities such as morbilliform drug reactions and infectious cellulitis. The severity of skin toxicity was graded according to Common Terminology Criteria for Adverse Events (CTCAE) Version 4.0.(122) (See appendix 1 for a definition of each skin toxicity grade). CTCAE, published by National Cancer Institute, is a widely accepted grading scale in oncology research community as the standard grading system for adverse events. Its version 4.0 was published in May 2009. Descriptive statistical analysis, contingency table, and Fischer's exact test were used to analyze the data.

Bingnan Zhang collected the data and conducted the literature review for this project. Katherine Mandock extracted the pharmacy data for the patients studied. Bingnan Zhang, Peter Marks, Jean

Bologna, and Nikolai Podoltsev contributed to the analysis and writing of the methods, results, and discussion section of the thesis.

## **Results**

Table 1 shows the demographics and diagnoses of the 10 patients treated with clofarabine alone and the 40 patients treated with a combination of clofarabine plus cytarabine. Note that one patient received both of these regimens, but the latter were separated by a sufficiently long time interval (6 weeks) such that the two courses were considered separate exposures. The mean age at time of treatment was 47 years, ranging between 20 to 77 years. About three quarters of the patients had acute myeloid leukemia, and the rest had acute lymphoid leukemia. All of the patients had relapsed or primary refractory disease, and approximately 40% of the patients had previously undergone an allogeneic hematopoietic stem cell transplant.

Table 2 outlines the types of cutaneous reactions seen in the patients in this series. The former are subdivided into those related to clofarabine and/or cytarabine and those that were due to other medications, fever, or the underlying hematologic malignancy. Twenty-two of 40 patients who received clofarabine plus cytarabine developed chemotherapy-related skin reactions, the majority of which

were toxic in nature rather than allergic. Of the four patients who developed erythroderma, three were assessed as grade 3 and one as grade 5 (Figure 3)(122). The medical records notes for the patient with grade 5 erythroderma recorded, on day two of clofarabine plus cytarabine treatment, the patient developed "whole body rash", on day five of the treatment, "erythematous rash involving his trunk and extremities, which was thought secondary to clofarabine and cytarabine", day six, "blistering developed in bilateral leg, large bullae developed below knees ranging in size from 0.5cm to 15cm diameter, dermatology suspected toxic erythema of chemotherapy, further developing into epidermal necrolysis. Day seven, patient admitted into ICU for "sepsis and hypoxic respiratory failure, significant leg tenderness with diffuse bullae over his feet and lower extremities", and the patient deceased shortly after. A typical description of palmar-plantar erythrodysesthesia in the medical chart is as follows: On day 4 after chemotherapy treatment started, patient developed "pain and burning in bilateral hands and feet, oral pyridoxine was started"; on day 5, "hands and feet become edematous and erythematous, painful"; day 8, "hands and feet remain diffusely erythematous and swollen, skin is dry and beginning to peel, less pain", day 13, "improved erythema with sloughing of dry skin over palms and soles", day 15, resolved.



When the two groups were compared, chemotherapy-related cutaneous reactions were seen more often in the group receiving the combination of clofarabine plus cytarabine (55% [22/40 patients]) than in those receiving clofarabine alone (10% [1/10 patients];  $p=0.014$ ). Of note, all four patients who developed erythroderma received the clofarabine and cytarabine combination regimen. In addition (not included in the table), one patient developed leukemia cutis in the clofarabine alone group, and one patient developed petechiae due to thrombocytopenia in the combination group. The non-chemotherapy – related skin reactions include Morbilliform drug reaction to cephalosporin, Miliaria crystallina, and Sweet’s syndrome, and all of which occurred in the combination therapy group.

All of the patients developed TEC between day 3 and day 9 post administration of chemotherapy, and all but one of the skin eruptions appeared within the first week of chemotherapy administration. The majority of skin symptoms were resolved within two to three weeks. In terms of location of the chemotherapy-related skin eruptions, hand and foot involvement were present in 16 out of 23 patients (70%), leg involvement were present in 6 patients (26%), arm involvement in 4

patients (17%), and abdomen and buttock involvement were found in 2 patients (9%).

Five patients in the study had received multiple cycles of the clofarabine only or the combination chemotherapy regimen, and one patient received one cycle of each regimen. All were separated by sufficiently long time intervals so they were considered separate exposures. Of note, one patient who received the combination regimen twice developed erythroderma in both incidences. Another patient who received the combination regimen twice developed palmar-plantar erythrodysesthesia during the first cycle, and developed miliaria crystallina during the second cycle. The rest of them did not develop chemotherapy-related skin toxicities despite multiple cycles of one regimen. Due to the small sample size, we could not make meaningful conclusions in regards to the correlation between number of cycles and the incidence of skin toxicity, nor could we conclude if prior skin toxicity would predict the same skin toxicity reaction during the second exposure.

In terms of treatment for TEC that patients received in this series, the majority of them received oral pyridoxine 100mg TID, petroleum jelly based ointment, and one patient received Xeroform®

wound care for severe skin desquamation and blistering. A few of the patients did not receive any treatment.

### **Discussion:**

The development of toxic chemotherapy-related skin reactions in over half of the patients who received the combination of clofarabine plus cytarabine is clinically important (Table 2). In the series by Faderl et al.(120), where patients received the same regimen as in our series, two-thirds developed a cutaneous eruption that was described as either a non-specific skin rash or hand-foot syndrome, and when a similar regimen (but with a reduced dose of clofarabine [30mg/m<sup>2</sup>]) was utilized for reduced-intensity conditioning prior to allogeneic hematopoietic stem cell transplant, skin toxicity was observed in 56% of patients(123). In this latter group, approximately two-thirds of those with skin toxicities had hand-foot syndrome, with no specific descriptions for the remainder. Compared to clofarabine alone, there was statistically significant (p=0.014) enhanced cutaneous toxicity with the combination regimen in our series.

Our report emphasizes the range of toxic reactions that can occur as a manifestation of TEC. While allergic drug reactions may

generalize and lead to erythroderma, it should be noted that an erythroderma due to severe TEC is toxic in nature and can be managed by dose reduction in the next treatment cycle. In addition, when bullae develop within the areas of diffuse erythema, the misdiagnosis of toxic epidermal necrolysis (TEN) may be rendered, as in the initial dermatology consult notes in one patient with grade IV erythroderma. Because of the overlap in the histologic features of TEN versus erythrodermic TEC with bullae, the distinction is based primarily on clinical findings, in particular the initial sites of involvement and the stability of the bullae. The life-threatening nature of severe TEC due to clofarabine plus cytarabine was highlighted by a recent case report (121) as well as our patient depicted in Figure 2. The onset of TEC is typically within 2 days to 3 weeks after the chemotherapy administration,(4) and in our series, the onset for almost all the patients was within the first week, which warrants attention of the clinicians to monitor closely the skin changes during the first week of the administration of clofarabine with or without cytarabine.

Although there are reports and opinions that oral pyridoxine may prevent or lead to improvement of palmar-plantar erythrodysesthesia,(85) recent randomized, double-blind trials of oral pyridoxine versus placebo found no significant effect on the prevention

of hand-foot syndrome.(86, 87) Supportive care is essential for patients who have developed TEC and when it is severe, ICU-level care is often required. Treatment measures include pain control and placing windows in the most dependent portions of bullae in order to allow drainage of initially sterile fluid while preserving the blister roof as a “natural bandage”. Recognizing the toxic nature of the cutaneous reaction, followed by dose reductions in the future, are key elements of patient care.

There are several limitations of the study. First, it is a retrospective chart review study, therefore the descriptions and grading of skin toxicities are based on the chart descriptions, as oppose to real time observations. Second, the small sample size limited statistical significance of analyses including the implication of multiple cycles and previous exposures in correlation with skin eruptions. Third, the scope of the study is restricted to a specific regimen of clofarabine and cytarabine. Therefore a dose-response of the skin toxicity could not be studied.

In conclusion, this retrospective study indicated that TEC, ranging from palmar-plantar erythrodyesthesia, to erythema of major body folds to diffuse erythema, were more frequently observed in

patients receiving clofarabine (40mg/m<sup>2</sup>/d x 5 d) plus cytarabine (1g/m<sup>2</sup>/d for 5 d) compared to clofarabine at the same dose alone. The majority of cutaneous skin toxicities in this regimen is TEC, which typically occurs within the first week. Clinicians should be aware of the differential diagnosis of cutaneous toxicities and have a high suspicion for the development of TEC with the combination therapy.

#### References:

1. . American Cancer Society. Cancer Facts&Figures 2013. <http://www.cancer.org/research/cancerfactsstatistics/cancerfactsfigures2013/index>. Accessed Aug.3rd, 2013.
2. Balagula Y, Rosen ST, and Lacouture ME. The emergence of supportive oncodermatology: the study of dermatologic adverse events to cancer therapies. *Journal of the American Academy of Dermatology*. 2011;65(3):624-35.
3. Heidary N, Naik H, and Burgin S. Chemotherapeutic agents and the skin: An update. *Journal of the American Academy of Dermatology*. 2008;58(4):545-70.
4. Bologna JL, Cooper DL, and Glusac EJ. Toxic erythema of chemotherapy: a useful clinical term. *Journal of the American Academy of Dermatology*. 2008;59(3):524-9.
5. Kimyai-Asadi A, and Jih MH. Follicular toxic effects of chimeric anti-epidermal growth factor receptor antibody cetuximab used to treat human solid tumors. *Archives of dermatology*. 2002;138(1):129-31.
6. Segaeert S, and Van Cutsem E. Clinical signs, pathophysiology and management of skin toxicity during therapy with epidermal growth factor receptor inhibitors. *Annals of oncology : official journal of the European Society for Medical Oncology / ESMO*. 2005;16(9):1425-33.
7. Kris MG, Natale RB, Herbst RS, Lynch TJ, Jr., Prager D, Belani CP, Schiller JH, Kelly K, Spiridonidis H, Sandler A, et al. Efficacy of gefitinib, an inhibitor of the epidermal growth factor receptor tyrosine kinase, in symptomatic patients with non-small cell lung cancer: a randomized trial. *JAMA : the journal of the American Medical Association*. 2003;290(16):2149-58.
8. Cohen EE, Rosen F, Stadler WM, Recant W, Stenson K, Huo D, and Vokes EE. Phase II trial of ZD1839 in recurrent or metastatic squamous cell carcinoma

- of the head and neck. *Journal of clinical oncology : official journal of the American Society of Clinical Oncology*. 2003;21(10):1980-7.
9. Needle MN. Safety experience with IMC-C225, an anti-epidermal growth factor receptor antibody. *Seminars in oncology*. 2002;29(5 Suppl 14):55-60.
  10. Perez-Soler R. Can rash associated with HER1/EGFR inhibition be used as a marker of treatment outcome? *Oncology (Williston Park)*. 2003;17(11 Suppl 12):23-8.
  11. Perez-Soler R, Chachoua A, Hammond LA, Rowinsky EK, Huberman M, Karp D, Rigas J, Clark GM, Santabarbara P, and Bonomi P. Determinants of tumor response and survival with erlotinib in patients with non--small-cell lung cancer. *Journal of clinical oncology : official journal of the American Society of Clinical Oncology*. 2004;22(16):3238-47.
  12. Baselga J. The EGFR as a target for anticancer therapy--focus on cetuximab. *Eur J Cancer*. 2001;37 Suppl 4(S16-22).
  13. Wyatt AJ, Leonard GD, and Sachs DL. Cutaneous reactions to chemotherapy and their management. *American journal of clinical dermatology*. 2006;7(1):45-63.
  14. Micantonio T, Fagnoli MC, Ricevuto E, Ficorella C, Marchetti P, and Peris K. Efficacy of treatment with tetracyclines to prevent acneiform eruption secondary to cetuximab therapy. *Archives of dermatology*. 2005;141(9):1173-4.
  15. Fukuoka M, Yano S, Giaccone G, Tamura T, Nakagawa K, Douillard JY, Nishiwaki Y, Vansteenkiste J, Kudoh S, Rischin D, et al. Multi-institutional randomized phase II trial of gefitinib for previously treated patients with advanced non-small-cell lung cancer (The IDEAL 1 Trial) [corrected]. *Journal of clinical oncology : official journal of the American Society of Clinical Oncology*. 2003;21(12):2237-46.
  16. Matheis P, Socinski MA, Burkhart C, Warren S, and Thomas NE. Treatment of gefitinib-associated folliculitis. *Journal of the American Academy of Dermatology*. 2006;55(4):710-3.
  17. Revuz J, and Valeyrie-Allanore L. In: Bologna jL, Jorizzo JL, and Schaffer JV eds. *Dermatology*. Elsevier 2012:350 pp.
  18. Cetkovska P, Pizinger K, and Cetkovsky P. High-dose cytosine arabinoside-induced cutaneous reactions. *Journal of the European Academy of Dermatology and Venereology : JEADV*. 2002;16(5):481-5.
  19. Litt J. *Drug eruption reference manual*. New York (NY): Parthenon Publishing Group Inc; 2003.
  20. Hussein MA, and Anderson KC. Role of liposomal anthracyclines in the treatment of multiple myeloma. *Seminars in oncology*. 2004;31(6 Suppl 13):147-60.
  21. Montagut C, Grau JJ, Grimalt R, Codony J, Ferrando J, and Albanell J. Abnormal hair growth in a patient with head and neck cancer treated with the anti-epidermal growth factor receptor monoclonal antibody cetuximab. *Journal of clinical oncology : official journal of the American Society of Clinical Oncology*. 2005;23(22):5273-5.

22. Bouche O, Brixi-Benmansour H, Bertin A, Perceau G, and Lagarde S. Trichomegaly of the eyelashes following treatment with cetuximab. *Annals of oncology : official journal of the European Society for Medical Oncology / ESMO*. 2005;16(10):1711-2.
23. Dueland S, Sauer T, Lund-Johansen F, Ostenstad B, and Tveit KM. Epidermal growth factor receptor inhibition induces trichomegaly. *Acta Oncol*. 2003;42(4):345-6.
24. Pesce A, Cassuto JP, Joyner MV, DuJardin P, and Audoly P. Scalp tourniquet in the prevention of chemotherapy-induced alopecia. *The New England journal of medicine*. 1978;298(21):1204-5.
25. Duvic M, Lemak NA, Valero V, Hymes SR, Farmer KL, Hortobagyi GN, Trancik RJ, Bandstra BA, and Compton LD. A randomized trial of minoxidil in chemotherapy-induced alopecia. *Journal of the American Academy of Dermatology*. 1996;35(1):74-8.
26. Betticher DC, Delmore G, Breitenstein U, Anchisi S, Zimmerli-Schwab B, Muller A, von Moos R, Hugli-Dayer AM, Schefer H, Bodenmann S, et al. Efficacy and tolerability of two scalp cooling systems for the prevention of alopecia associated with docetaxel treatment. *Supportive care in cancer : official journal of the Multinational Association of Supportive Care in Cancer*. 2013;21(9):2565-73.
27. Sokumbi O, and Wetter DA. Clinical features, diagnosis, and treatment of erythema multiforme: a review for the practicing dermatologist. *International journal of dermatology*. 2012;51(8):889-902.
28. Huff JC, Weston WL, and Tonnesen MG. Erythema multiforme: a critical review of characteristics, diagnostic criteria, and causes. *Journal of the American Academy of Dermatology*. 1983;8(6):763-75.
29. Chung WH, and Hung SI. Recent advances in the genetics and immunology of Stevens-Johnson syndrome and toxic epidermal necrosis. *Journal of dermatological science*. 2012;66(3):190-6.
30. Chung WH, Hung SI, Hong HS, Hsieh MS, Yang LC, Ho HC, Wu JY, and Chen YT. Medical genetics: a marker for Stevens-Johnson syndrome. *Nature*. 2004;428(6982):486.
31. Hung SI, Chung WH, Liou LB, Chu CC, Lin M, Huang HP, Lin YL, Lan JL, Yang LC, Hong HS, et al. HLA-B\*5801 allele as a genetic marker for severe cutaneous adverse reactions caused by allopurinol. *Proceedings of the National Academy of Sciences of the United States of America*. 2005;102(11):4134-9.
32. Lo SK, Yip D, Leslie M, and Harper P. 5-fluorouracil-induced erythema multiforme. *International journal of clinical practice*. 1999;53(3):219-21.
33. Hirai K, Ishiko O, Nakajima S, Kanaoka Y, Nakamura Y, Oiso N, Ishii M, and Ogita S. Local erythematous dermatitis after intravenous docetaxel. *Gynecologic and obstetric investigation*. 2002;53(2):118-20.
34. French LE, and Prins C. In: Bologna JL, Jorizzo JL, and Schaffer JV eds. *Dermatology*. Elsevier; 2012:322pp.
35. Sommers KR, Kong KM, Bui DT, Fruehauf JP, and Holcombe RF. Stevens-Johnson syndrome/toxic epidermal necrolysis in a patient receiving concurrent radiation and gemcitabine. *Anti-cancer drugs*. 2003;14(8):659-62.



36. Lowndes S, Darby A, Mead G, and Lister A. Stevens-Johnson syndrome after treatment with rituximab. *Annals of oncology : official journal of the European Society for Medical Oncology / ESMO*. 2002;13(12):1948-50.
37. Arias D, Requena L, Hasson A, Gutierrez M, Domine M, Martin L, and Barat A. Localized epidermal necrolysis (erythema multiforme-like reaction) following intravenous injection of vinblastine. *Journal of cutaneous pathology*. 1991;18(5):344-6.
38. Kelemen JJ, 3rd, Cioffi WG, McManus WF, Mason AD, Jr., and Pruitt BA, Jr. Burn center care for patients with toxic epidermal necrolysis. *Journal of the American College of Surgeons*. 1995;180(3):273-8.
39. Prins C, Kerdel FA, Padilla RS, Hunziker T, Chimenti S, Viard I, Mauri DN, Flynn K, Trent J, Margolis DJ, et al. Treatment of toxic epidermal necrolysis with high-dose intravenous immunoglobulins: multicenter retrospective analysis of 48 consecutive cases. *Archives of dermatology*. 2003;139(1):26-32.
40. Coombs RRA, and Gell PGH. In: Gell PGH, Coombs RRA, and Lachmann PJ eds. *Clinical Aspects of Immunology*. Oxford: Blackwells; 1975:761-81.
41. Moon C, Verschraegen CF, Bevers M, Freedman R, Kudelka AP, and Kavanagh JJ. Use of docetaxel (Taxotere) in patients with paclitaxel (Taxol) hypersensitivity. *Anti-cancer drugs*. 2000;11(7):565-8.
42. Markman M, Kennedy A, Webster K, Elson P, Peterson G, Kulp B, and Belinson J. Clinical features of hypersensitivity reactions to carboplatin. *Journal of clinical oncology : official journal of the American Society of Clinical Oncology*. 1999;17(4):1141.
43. Porzio G, Marchetti P, Paris I, Narducci F, Ricevuto E, and Ficorella C. Hypersensitivity reaction to carboplatin: successful resolution by replacement with cisplatin. *European journal of gynaecological oncology*. 2002;23(4):335-6.
44. Otrrock ZK, Mahfouz RA, Oghlakian GO, Salem ZM, and Bazarbachi A. Rituximab-induced acute thrombocytopenia: a report of two cases. *Haematologica*. 2005;90 Suppl(ECR23).
45. Voog E, Morschhauser F, and Solal-Celigny P. Neutropenia in patients treated with rituximab. *The New England journal of medicine*. 2003;348(26):2691-4; discussion -4.
46. Kim MJ, Kim HO, Kim HY, and Park YM. Rituximab-induced vasculitis: A case report and review of the medical published work. *The Journal of dermatology*. 2009;36(5):284-7.
47. Le Guenno G, Ruivard M, Charra L, and Philippe P. Rituximab-induced serum sickness in refractory immune thrombocytopenic purpura. *Internal medicine journal*. 2011;41(2):202-5.
48. Baldo BA. Adverse events to monoclonal antibodies used for cancer therapy: Focus on hypersensitivity responses. *Oncoimmunology*. 2013;2(10):e26333.
49. Robak T, Blasinska-Morawiec M, Krykowski E, Hellmann A, Lewandowski K, Dmoszynska A, Adamczyk-Cioch M, Kazimierzczak M, Trepinska E, Dwilewicz-Trojaczek M, et al. 2-Chlorodeoxyadenosine (cladribine)-related eosinophilia in patients with lymphoproliferative diseases. *European journal of haematology*. 1997;59(4):216-20.

50. Young PC, Montemarano AD, Lee N, Sau P, Weiss RB, and James WD. Hypersensitivity to paclitaxel manifested as a bullous fixed drug eruption. *Journal of the American Academy of Dermatology*. 1996;34(2 Pt 1):313-4.
51. Lautenschlager S, and Itin PH. Reticulate, patchy and mottled pigmentation of the neck. Acquired forms. *Dermatology*. 1998;197(3):291-6.
52. Youssef M, Mokni S, Belhadjali H, Aouem K, Moussa A, Laatiri A, and Zili J. Cyclophosphamide-induced generalised reticulated skin pigmentation: a rare presentation. *International journal of clinical pharmacy*. 2013;35(3):309-12.
53. Dave S, and Thappa DM. Peculiar pattern of nail pigmentation following cyclophosphamide therapy. *Dermatology online journal*. 2003;9(3):14.
54. Jeevankumar B, and Thappa DM. Blue lunula due to hydroxyurea. *The Journal of dermatology*. 2003;30(8):628-30.
55. Kumar B, Saraswat A, and Kaur I. Mucocutaneous adverse effects of hydroxyurea: a prospective study of 30 psoriasis patients. *Clinical and experimental dermatology*. 2002;27(1):8-13.
56. Schrijvers D, Van Den Brande J, and Vermorcken JB. Supravenous discoloration of the skin due to docetaxel treatment. *The British journal of dermatology*. 2000;142(5):1069-70.
57. van Oosterom AT, Schrijvers D, and Schrijvers D. Docetaxel (Taxotere), a review of preclinical and clinical experience. Part II: Clinical experience. *Anti-cancer drugs*. 1995;6(3):356-68.
58. Kroupouzios G, Travers R, and Allan A. Generalized hyperpigmentation with daunorubicin chemotherapy. *Journal of the American Academy of Dermatology*. 2002;46(2 Suppl Case Reports):S1-3.
59. Wong M, Sade S, Gilbert M, and Klieb HB. Oral melanosis after tyrosine kinase inhibition with Imatinib for chronic myelogenous leukemia: report of a case and review of the literature. *Dermatology online journal*. 2011;17(5):4.
60. Alexandrescu DT, Dasanu CA, Farzanmehr H, and Kauffman L. Persistent cutaneous hyperpigmentation after tyrosine kinase inhibition with imatinib for GIST. *Dermatology online journal*. 2008;14(7):7.
61. Bensadoun RJ, Humbert P, Krutman J, Luger T, Triller R, Rougier A, Seite S, and Dreno B. Daily baseline skin care in the prevention, treatment, and supportive care of skin toxicity in oncology patients: recommendations from a multinational expert panel. *Cancer management and research*. 2013;5(401-8).
62. Van Doorn R, Kirtschig G, Scheffer E, Stoof TJ, and Giaccone G. Follicular and epidermal alterations in patients treated with ZD1839 (Iressa), an inhibitor of the epidermal growth factor receptor. *The British journal of dermatology*. 2002;147(3):598-601.
63. Herbst RS, LoRusso PM, Purdom M, and Ward D. Dermatologic side effects associated with gefitinib therapy: clinical experience and management. *Clinical lung cancer*. 2003;4(6):366-9.
64. Hu JC, Sadeghi P, Pinter-Brown LC, Yashar S, and Chiu MW. Cutaneous side effects of epidermal growth factor receptor inhibitors: clinical presentation, pathogenesis, and management. *Journal of the American Academy of Dermatology*. 2007;56(2):317-26.

65. Liu S, Herault Y, Pavlovic G, and Leask A. Skin progenitor cells contribute to bleomycin-induced skin fibrosis. *Arthritis and rheumatism*. 2013.
66. Dacey MJ, and Callen JP. Hydroxyurea-induced dermatomyositis-like eruption. *Journal of the American Academy of Dermatology*. 2003;48(3):439-41.
67. Vasconcelos I, and Schoenegg W. Massive breast necrosis after extravasation of a full anthracycline cycle. *BMJ case reports*. 2013;2013(
68. Wilson J, Carder P, Gooi J, and Nishikawa H. Recall phenomenon following epirubicin. *Clinical oncology*. 1999;11(6):424-5.
69. Naidu MU, Ramana GV, Rani PU, Mohan IK, Suman A, and Roy P. Chemotherapy-induced and/or radiation therapy-induced oral mucositis--complicating the treatment of cancer. *Neoplasia*. 2004;6(5):423-31.
70. Tsukada T, Nakano T, Miyata T, and Sasaki S. Life-Threatening Gastrointestinal Mucosal Necrosis during Methotrexate Treatment for Rheumatoid Arthritis. *Case reports in gastroenterology*. 2013;7(3):470-5.
71. Oksenhendler E, Landais P, Cordonnier C, Kuentz M, Bagot M, Jais JP, Roujeau JC, and Vernant JP. Acral erythema and systemic toxicity related to CHA induction therapy in acute myeloid leukemia. *European journal of cancer & clinical oncology*. 1989;25(8):1181-5.
72. Walker IR, Wilson WE, Sauder DN, Bengner AM, and Browman G. Cytarabine-induced palmar-plantar erythema. *Archives of dermatology*. 1985;121(10):1240-1.
73. Lokich JJ, and Moore C. Chemotherapy-associated palmar-plantar erythrodysesthesia syndrome. *Annals of internal medicine*. 1984;101(6):798-9.
74. Hansen R, Quebbeman E, Beatty P, Ritch P, Anderson T, Jenkins D, Frick J, and Ausman R. Continuous 5-fluorouracil infusion in refractory carcinoma of the breast. *Breast cancer research and treatment*. 1987;10(2):145-9.
75. Krulder JW, Vlasveld LT, and Willemze R. Erythema and swelling of ears after treatment with cytarabine for leukemia. *Eur J Cancer*. 1990;26(5):649-50.
76. Lee HY, and Chung WH. Toxic epidermal necrolysis: the year in review. *Current opinion in allergy and clinical immunology*. 2013;13(4):330-6.
77. Parker TL, Cooper DL, Seropian SE, and Bologna JL. Toxic erythema of chemotherapy following i.v. BU plus fludarabine for allogeneic PBSC transplant. *Bone marrow transplantation*. 2013;48(5):646-50.
78. Sterry W, and Steinhoff M. In: Bologna jL, Jorizzo JL, and Schaffer JV eds. *Dermatology*. Elsevier; 2012:171-81.
79. Nagore E, Insa A, and Sanmartin O. Antineoplastic therapy-induced palmar plantar erythrodysesthesia ('hand-foot') syndrome. Incidence, recognition and management. *American journal of clinical dermatology*. 2000;1(4):225-34.
80. Mangili G, Petrone M, Gentile C, De Marzi P, and Vigano R. Prevention strategies in palmar-plantar erythrodysesthesia onset: the role of regional cooling. *Gynecologic oncology*. 2008;108(2):332-5.
81. Drake RD, Lin WM, King M, Farrar D, Miller DS, and Coleman RL. Oral dexamethasone attenuates Doxil-induced palmar-plantar

- erythrodysesthesias in patients with recurrent gynecologic malignancies. *Gynecologic oncology*. 2004;94(2):320-4.
82. Gressett SM, Stanford BL, and Hardwicke F. Management of hand-foot syndrome induced by capecitabine. *Journal of oncology pharmacy practice : official publication of the International Society of Oncology Pharmacy Practitioners*. 2006;12(3):131-41.
  83. Lopez AM, Wallace L, Dorr RT, Koff M, Hersh EM, and Alberts DS. Topical DMSO treatment for pegylated liposomal doxorubicin-induced palmar-plantar erythrodysesthesia. *Cancer chemotherapy and pharmacology*. 1999;44(4):303-6.
  84. Zhang RX, Wu XJ, Wan DS, Lu ZH, Kong LH, Pan ZZ, and Chen G. Celecoxib can prevent capecitabine-related hand-foot syndrome in stage II and III colorectal cancer patients: result of a single-center, prospective randomized phase III trial. *Annals of oncology : official journal of the European Society for Medical Oncology / ESMO*. 2012;23(5):1348-53.
  85. von Moos R, Thuerlimann BJ, Aapro M, Rayson D, Harrold K, Sehouli J, Scotte F, Lorusso D, Dummer R, Lacouture ME, et al. Pegylated liposomal doxorubicin-associated hand-foot syndrome: recommendations of an international panel of experts. *Eur J Cancer*. 2008;44(6):781-90.
  86. von Gruenigen V, Frasure H, Fusco N, DeBernardo R, Elder mire E, Eaton S, and Waggoner S. A double-blind, randomized trial of pyridoxine versus placebo for the prevention of pegylated liposomal doxorubicin-related hand-foot syndrome in gynecologic oncology patients. *Cancer*. 2010;116(20):4735-43.
  87. Kang YK, Lee SS, Yoon DH, Lee SY, Chun YJ, Kim MS, Ryu MH, Chang HM, Lee JL, and Kim TW. Pyridoxine is not effective to prevent hand-foot syndrome associated with capecitabine therapy: results of a randomized, double-blind, placebo-controlled study. *Journal of clinical oncology : official journal of the American Society of Clinical Oncology*. 2010;28(24):3824-9.
  88. Grant-Kels J, Fedeles F, and Rothe M. In: Goldsmith L, Katz S, Gilchrist B, Paller A, Leffell D, and Wolff K eds. *Fitzpatrick's Dermatology in General Medicine*. McGraw-Hill; 2012.
  89. Vasconcellos C, Domingues PP, Aoki V, Miyake RK, Sauaia N, and Martins JE. Erythroderma: analysis of 247 cases. *Revista de saude publica*. 1995;29(3):177-82.
  90. Khaled A, Sellami A, Fazaa B, Kharfi M, Zeglaoui F, and Kamoun MR. Acquired erythroderma in adults: a clinical and prognostic study. *Journal of the European Academy of Dermatology and Venereology : JEADV*. 2010;24(7):781-8.
  91. Li J, and Zheng HY. Erythroderma: a clinical and prognostic study. *Dermatology*. 2012;225(2):154-62.
  92. Akhyani M, Ghodsi ZS, Toosi S, and Dabbaghian H. Erythroderma: a clinical study of 97 cases. *BMC dermatology*. 2005;5(5).
  93. Fossa A, Santoro A, Hiddemann W, Truemper L, Niederle N, Buksmaui S, Bonadonna G, Seeber S, and Nowrousian MR. Gemcitabine as a single agent in the treatment of relapsed or refractory aggressive non-Hodgkin's lymphoma.

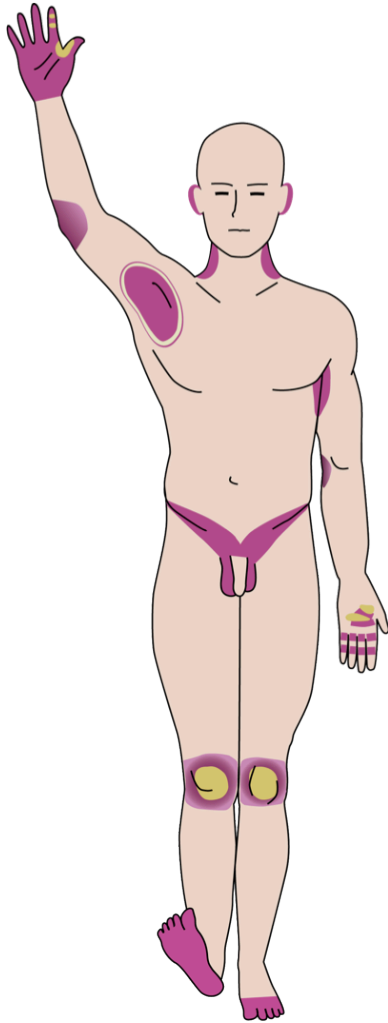
- Journal of clinical oncology : official journal of the American Society of Clinical Oncology.* 1999;17(12):3786-92.
94. Silverman LR, Demakos EP, Peterson BL, Kornblith AB, Holland JC, Odchimar-Reissig R, Stone RM, Nelson D, Powell BL, DeCastro CM, et al. Randomized controlled trial of azacitidine in patients with the myelodysplastic syndrome: a study of the cancer and leukemia group B. *Journal of clinical oncology : official journal of the American Society of Clinical Oncology.* 2002;20(10):2429-40.
  95. Wijermans P, Lubbert M, Verhoef G, Bosly A, Ravoet C, Andre M, and Ferrant A. Low-dose 5-aza-2'-deoxycytidine, a DNA hypomethylating agent, for the treatment of high-risk myelodysplastic syndrome: a multicenter phase II study in elderly patients. *Journal of clinical oncology : official journal of the American Society of Clinical Oncology.* 2000;18(5):956-62.
  96. Goodman GR, Burian C, Koziol JA, and Saven A. Extended follow-up of patients with hairy cell leukemia after treatment with cladribine. *Journal of clinical oncology : official journal of the American Society of Clinical Oncology.* 2003;21(5):891-6.
  97. Estey E, Thall P, Andreeff M, Beran M, Kantarjian H, O'Brien S, Escudier S, Robertson LE, Koller C, Kornblau S, et al. Use of granulocyte colony-stimulating factor before, during, and after fludarabine plus cytarabine induction therapy of newly diagnosed acute myelogenous leukemia or myelodysplastic syndromes: comparison with fludarabine plus cytarabine without granulocyte colony-stimulating factor. *Journal of clinical oncology : official journal of the American Society of Clinical Oncology.* 1994;12(4):671-8.
  98. Hiddemann W. Cytosine arabinoside in the treatment of acute myeloid leukemia: the role and place of high-dose regimens. *Annals of hematology.* 1991;62(4):119-28.
  99. Ho DH. Distribution of kinase and deaminase of 1-beta-D-arabinofuranosylcytosine in tissues of man and mouse. *Cancer research.* 1973;33(11):2816-20.
  100. Wodinsky I, and Kensler CJ. Activity of cytosine arabinoside (NSC-63878) in a spectrum of rodent tumors. *Cancer chemotherapy reports Part 1.* 1965;47(65-8).
  101. Ellison RR, Holland JF, Weil M, Jacquillat C, Boiron M, Bernard J, Sawitsky A, Rosner F, Gussoff B, Silver RT, et al. Arabinosyl cytosine: a useful agent in the treatment of acute leukemia in adults. *Blood.* 1968;32(4):507-23.
  102. Hassanein M, Atenafu EG, Schuh AC, Yee KW, Minden MD, Schimmer AD, Gupta V, and Brandwein JM. High-dose cytarabine-based consolidation shows superior results for older AML patients with intermediate risk cytogenetics in first complete remission. *Leukemia research.* 2013;37(5):556-60.
  103. Scappini B, Gianfaldoni G, Caracciolo F, Mannelli F, Biagiotti C, Romani C, Pogliani EM, Simonetti F, Borin L, Fanci R, et al. Cytarabine and clofarabine after high-dose cytarabine in relapsed or refractory AML patients. *American journal of hematology.* 2012;87(12):1047-51.



104. Sandlund JT, Santana VM, Hudson MM, Onciu M, Head D, Murry DJ, Ribeiro R, Wallace D, Rencher R, and Pui CH. Combination of dexamethasone, high-dose cytarabine, and carboplatin is effective for advanced large-cell non-Hodgkin lymphoma of childhood. *Cancer*. 2008;113(4):782-90.
105. Stock W, Johnson JL, Stone RM, Kolitz JE, Powell BL, Wetzler M, Westervelt P, Marcucci G, DeAngelo DJ, Vardiman JW, et al. Dose intensification of daunorubicin and cytarabine during treatment of adult acute lymphoblastic leukemia: results of Cancer and Leukemia Group B Study 19802. *Cancer*. 2013;119(1):90-8.
106. Stone RM, Donohue KA, Stock W, Hars V, Linker CA, Shea T, Deangelo DJ, Marcucci G, Bloomfield CD, and Larson RA. A phase II study of continuous infusion homoharringtonine and cytarabine in newly diagnosed patients with chronic myeloid leukemia: CALGB study 19804. *Cancer chemotherapy and pharmacology*. 2009;63(5):859-64.
107. Montgomery JA, Shortnacy-Fowler AT, Clayton SD, Riordan JM, and Secrist JA, 3rd. Synthesis and biologic activity of 2'-fluoro-2-halo derivatives of 9-beta-D-arabinofuranosyladenine. *Journal of medicinal chemistry*. 1992;35(2):397-401.
108. Zhenchuk A, Lotfi K, Juliusson G, and Albertioni F. Mechanisms of anti-cancer action and pharmacology of clofarabine. *Biochemical pharmacology*. 2009;78(11):1351-9.
109. Gandhi V, Kantarjian H, Faderl S, Bonate P, Du M, Ayres M, Rios MB, Keating MJ, and Plunkett W. Pharmacokinetics and pharmacodynamics of plasma clofarabine and cellular clofarabine triphosphate in patients with acute leukemias. *Clinical cancer research : an official journal of the American Association for Cancer Research*. 2003;9(17):6335-42.
110. . Clolar (Clofarabine) Prescribing Information. <http://www.clolar.com>. Accessed Aug.6, 2013.
111. Faderl S, Wetzler M, Rizzieri D, Schiller G, Jagasia M, Stuart R, Ganguly S, Avigan D, Craig M, Collins R, et al. Clofarabine plus cytarabine compared with cytarabine alone in older patients with relapsed or refractory acute myelogenous leukemia: results from the CLASSIC I Trial. *Journal of clinical oncology : official journal of the American Society of Clinical Oncology*. 2012;30(20):2492-9.
112. Faderl S, Ravandi F, Huang X, Garcia-Manero G, Ferrajoli A, Estrov Z, Borthakur G, Verstovsek S, Thomas DA, Kwari M, et al. A randomized study of clofarabine versus clofarabine plus low-dose cytarabine as front-line therapy for patients aged 60 years and older with acute myeloid leukemia and high-risk myelodysplastic syndrome. *Blood*. 2008;112(5):1638-45.
113. Barba P, Sampol A, Calbacho M, Gonzalez J, Serrano J, Martinez-Sanchez P, Fernandez P, Garcia-Boyer R, Bueno J, and Ribera JM. Clofarabine-based chemotherapy for relapsed/refractory adult acute lymphoblastic leukemia and lymphoblastic lymphoma. The Spanish experience. *American journal of hematology*. 2012;87(6):631-4.
114. . Acue Myeloid Leukemia. <http://www.nccn.org>. Accessed Aug.5, 2013.

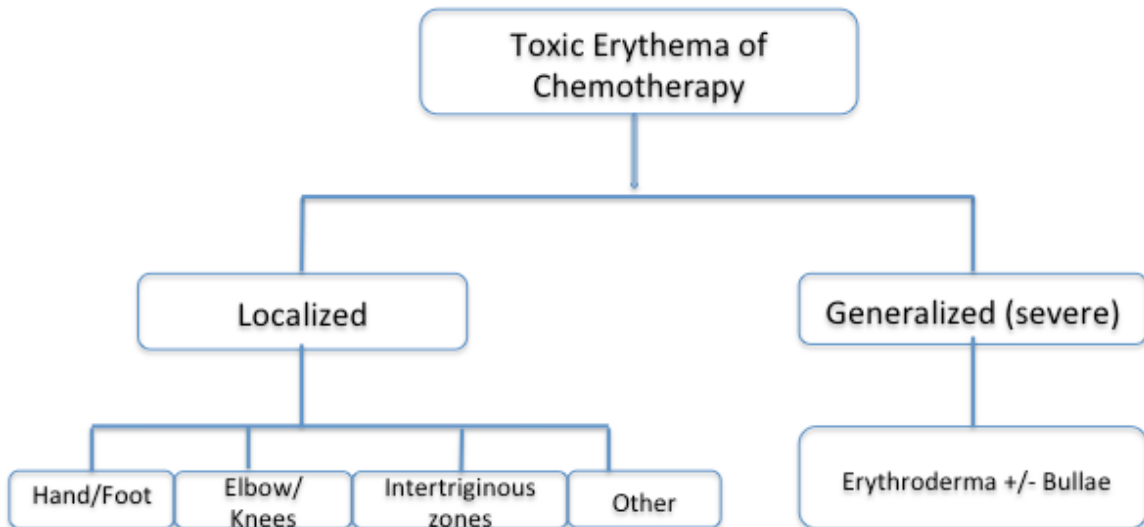
115. Faderl S, Verstovsek S, Cortes J, Ravandi F, Beran M, Garcia-Manero G, Ferrajoli A, Estrov Z, O'Brien S, Koller C, et al. Clofarabine and cytarabine combination as induction therapy for acute myeloid leukemia (AML) in patients 50 years of age or older. *Blood*. 2006;108(1):45-51.
116. Nazha A, Kantarjian H, Ravandi F, Huang X, Choi S, Garcia-Manero G, Jabbour E, Borthakur G, Kadia T, Konopleva M, et al. Clofarabine, idarubicin, and cytarabine (CIA) as frontline therapy for patients  $\leq$  60 years with newly diagnosed acute myeloid leukemia (AML). *American journal of hematology*. 2013.
117. Horn TD. Antineoplastic chemotherapy, sweat, and the skin. *Archives of dermatology*. 1997;133(7):905-6.
118. Jacobi U, Waibler E, Schulze P, Sehouli J, Oskay-Ozcelik G, Schmook T, Sterry W, and Lademann J. Release of doxorubicin in sweat: first step to induce the palmar-plantar erythrodysesthesia syndrome? *Annals of oncology : official journal of the European Society for Medical Oncology / ESMO*. 2005;16(7):1210-1.
119. Kantarjian H, Gandhi V, Cortes J, Verstovsek S, Du M, Garcia-Manero G, Giles F, Faderl S, O'Brien S, Jeha S, et al. Phase 2 clinical and pharmacologic study of clofarabine in patients with refractory or relapsed acute leukemia. *Blood*. 2003;102(7):2379-86.
120. Faderl S, Gandhi V, O'Brien S, Bonate P, Cortes J, Estey E, Beran M, Wierda W, Garcia-Manero G, Ferrajoli A, et al. Results of a phase 1-2 study of clofarabine in combination with cytarabine (ara-C) in relapsed and refractory acute leukemias. *Blood*. 2005;105(3):940-7.
121. Hwang YY, Trendell-Smith NJ, Yeung CK, and Kwong YL. Fatal palmar-plantar erythrodysesthesia after clofarabine and cytarabine chemotherapy. *Acta haematologica*. 2012;128(3):151-3.
122. . *National Cancer Institute Common Terminology Criteria for Adverse Events v4.0 NIH publication #09-7473*. NCI, NIH, DHHS.; 2009.
123. Buchholz S, Dammann E, Stadler M, Krauter J, Beutel G, Trummer A, Eder M, and Ganser A. Cytoreductive treatment with clofarabine/ara-C combined with reduced-intensity conditioning and allogeneic stem cell transplantation in patients with high-risk, relapsed, or refractory acute myeloid leukemia and advanced myelodysplastic syndrome. *European journal of haematology*. 2012;88(1):52-60.

**Figure 1: Distribution pattern for toxic erythema of chemotherapy (TEC).** The number of sites involved varies but the distribution remains symmetrical. Areas of dusky erythema appear that may be associated with burning or pain as well as superimposed sterile bullae (represented in yellow). *Reproduced from Parker TL, Cooper DL, Seropian SE, Bologna JL. Toxic erythema of chemotherapy following i.v. BU plus fludarabine for allogeneic PBSC transplant. Bone Marrow Transplantation. 2013;48:646-50.*



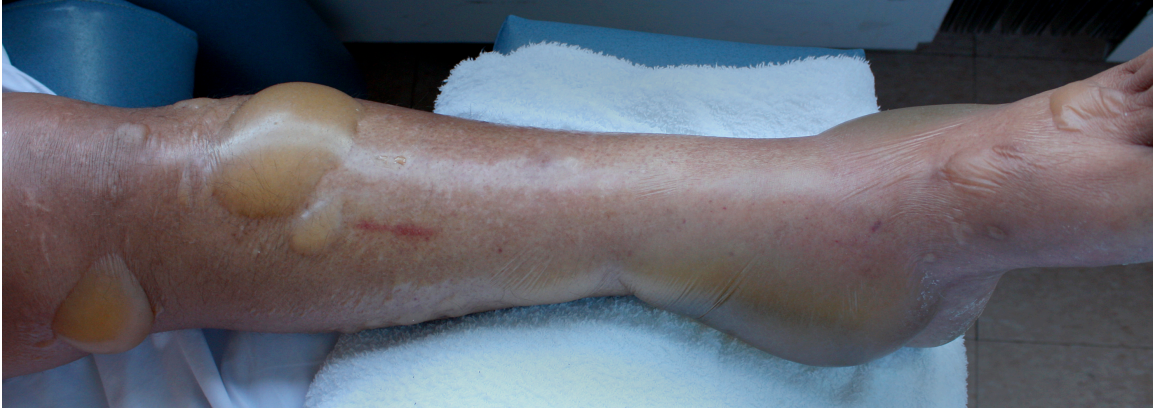

**Figure 2: A schematic presentation of the spectrum of toxic erythema of chemotherapy (TEC).**

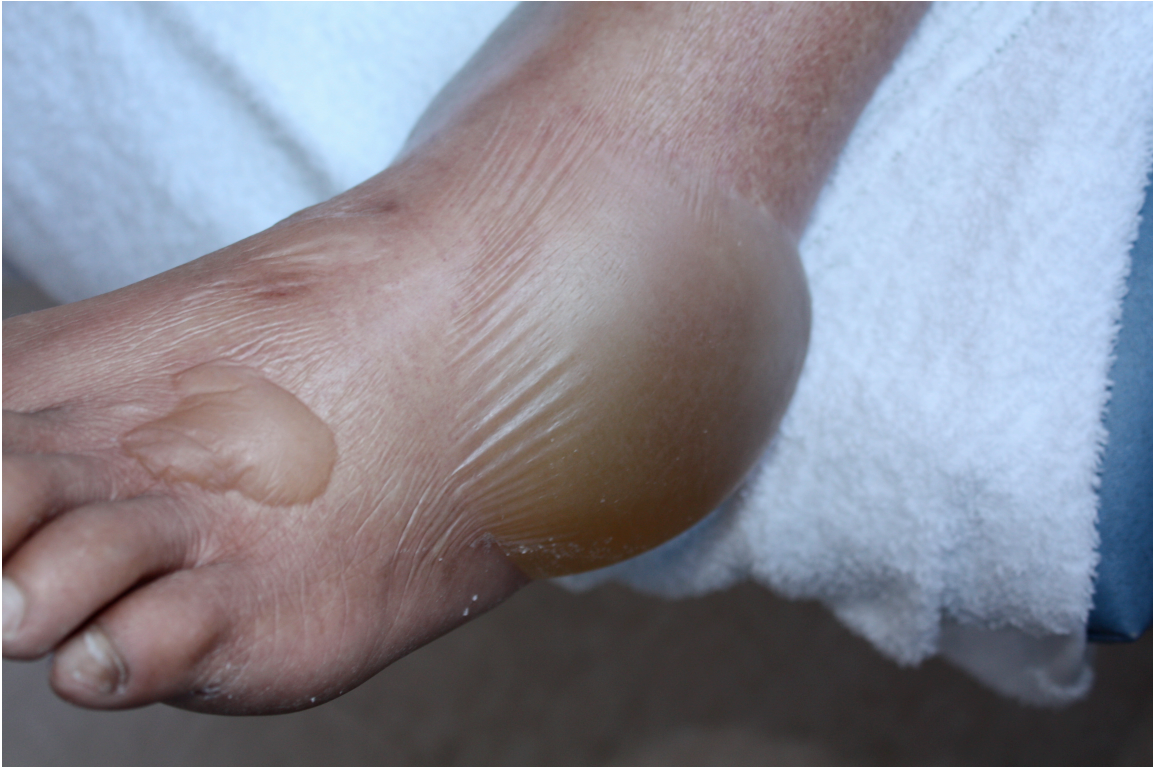

**Figure 3 A, B: Severe toxic erythema of chemotherapy (TEC) in a patient who received both clofarabine and cytarabine.** In occasional patients, the erythema becomes generalized, leading to an erythroderma that resembles a severe sunburn (but without sparing of non-sun-exposed sites). The superimposed bullae are more stable than is observed in toxic epidermal necrolysis.

A



B



**Table 1: Patient demographics, hematologic malignancies, and therapies.** The mean age at time of treatment was 47 years (range, 20-77 years).\*1 patient treated with both regimens; <sup>†</sup>4 patients had unknown transplant history.

Characteristics	No. of patients
Total	49
Sex	
Male	27
Female	22
Leukemia type	
Acute lymphoid leukemia	12
Acute myeloid leukemia	37
Disease status (prior to treatment)	
Primary refractory	21
Relapsed	28
Chemotherapeutic regimens*	
Clofarabine	10
Clofarabine plus cytarabine	40
Prior hematopoietic stem cell transplant <sup>†</sup>	
Allogeneic	1
Autologous	24
No	

**Table 2. Cutaneous reactions to the two chemotherapeutic regimens.** \*In addition, one patient developed leukemia cutis (clofarabine alone group) and one patient developed petechiae due to thrombocytopenia (clofarabine plus cytarabine group); \*\* Two patients developed bilateral non-infectious lower extremity erythema and one patient developed significant desquamation.

Cutaneous reaction*	Chemotherapeutic regimen (No. of patients)	
	Clofarabine	Clofarabine+cytarabine
<i>Chemotherapy-related</i>		
• Toxic erythema of chemotherapy		
- Palmar-plantar erythrodysesthesia	1	15
- Erythroderma (>90% BSA involvement)	0	4
- Other	0	3**
<i>Not chemotherapy-related</i>		
• Morbilliform drug reaction to cephalosporin	0	3
• Sweet's syndrome	0	1
• Miliaria crystallina	0	2

**Appendix:**

## CTCAE 4.3 grade &amp; definition

Erythroderma		Palmar-plantar erythrodysesthesia syndrome	
Grade	Definition	Grade	Definition
1	-	1	Minimal skin changes or dermatitis (e.g. erythema, edema, or hyperkeratosis) without pain
2	Erythema covering >90% BSA without associated symptoms, limiting instrumental ADL	2	Skin changes (e.g. peeling, blistering, bleeding, edema, or hyperkeratosis) with pain ; limiting instrumental ADL
3	Erythema covering >90% BSA with associated symptoms (e.g. pruritus or tenderness); limiting self care ADL	3	Severe skin changes (e.g. peeling, blisters, bleeding, edema, or hyperkeratosis) with pain, limiting self care ADL
4	Erythema covering >90% BSA with associated fluid or electrolyte abnormalities; ICU care or burn unit indicated	4	-
5	Death		-